

Cervical Spine Injuries in Sports

Andrew A Sama, MD, Director of Orthopedic Spine Surgery at the New York Hospital of Queens, Assistant Professor of Orthopedic Surgery at the Weill Medical College, Cornell University; Consulting Staff, Department of Orthopedic Surgery, Hospital for Special Surgery

Federico P Girardi, MD, Instructor, Department of Orthopedic Surgery, Weill College of Medicine of Cornell University; **Frank P Cammisa, Jr, MD**, Chief, Spinal Surgery Service, Director, Spine Care Institute, Hospital for Special Surgery; Associate Professor, Department of Clinical Orthopedic Surgery, Weill Medical College-Cornell University

Updated: Jun 25, 2008

Introduction

One of the most challenging roles of the team physician involves the intervention and decision-making processes regarding cervical spine (C-spine) injuries in contact sports. The team physician must be well versed in the prevention, evaluation, stabilization, and treatment of C-spine injuries. A high index of suspicion and an understanding of cervical alignment and architecture, as well as comprehension of the mechanics exerted during a sporting event, are imperative to diagnosing cervical injuries.^{1,2}

Well more than half of catastrophic injuries in sports are cervical spine injuries. C-spine injuries have been reported in most contact sports, including football, hockey, rugby, and wrestling, as well as in several noncontact sports, such as skiing, track and field, diving, surfing, power lifting, and equestrian events. C-spine injuries are estimated to occur in 10-15% of all football players, most commonly in linemen and defensive players. Serious injuries with neurologic sequelae remain infrequent, and most of these injuries are self-limited. Injuries occur in all levels of play, from the high school to the professional level.^{3,4,5}

Football and rugby have the highest incidence of C-spine injuries of all sports.^{6,7,8} Injury usually is secondary to high-velocity collisions between players, causing acceleration or deceleration of the head on the neck.⁹ Acceleration usually causes a whiplash type of extension force on the neck, while deceleration usually results in flexion forces.¹⁰ Spearing, which has been banned in American football since 1976, occurs when a player uses the helmet/head as the first point of contact with another player. Spearing is a significant cause of C-spine injuries and quadriplegia. The force transmitted to the cervical spine in these cases is one of axial compression with the vertebrae in positions of slight flexion.¹¹

The natural architecture of the normal C-spine assumes a lordosis of the vertebrae. This lordosis allows for controlled motion and the transmission of forces to the supporting muscles and soft tissues. When the neck is slightly flexed, approximately 30°, the normal lordosis is straightened, and the forces of the axial load are transmitted to the bones and disks. If the impact force is greater than the yield strength of the vertebrae, a fracture and possible dislocation with cord injury can occur.

Spectrum of injury

Cervical injuries that result from participation in sports usually are self-limited and can be divided into the following categories:

- Nerve root or brachial plexus injuries
- Acute cervical sprains/strains
- Intervertebral disk injuries
- Cervical fractures and dislocations
- Cervical stenosis

Related Medscape topics:

Resource Center Back Pain

Resource Center Exercise and Sports Medicine

Resource Center Fracture

Resource Center Spinal Disorders
Specialty Site Emergency Medicine

Case Q & A - Open Fractures

Epidemiology of Back Disorders: Prevalence, Risk Factors, and Prognosis

reFLEXIONS and rePERCUSSIONS: Goodley Intentions - Examining for Pains in the Neck

Nerve Root/Brachial Plexus Injuries

The most common cervical injury in football players is the transient loss of function with searing or lancing pain down one arm following a collision. These are colloquially referred to as stingers, or burners.^{12, 13} Prospective studies performed at Tulane University have shown a 7.7% incidence of stingers in a group of college football players. Initially, the player complains of total arm weakness and a radiating burning sensation that usually resolves. Numbness in the C-6 dermatomal distribution may persist. Motor weakness of shoulder abductors, elbow flexors, external humeral rotators, and wrist and finger extensors also may persist. The duration of symptoms is from 2-10 minutes to 24 hours. Symptoms are reproduced by the Spurling maneuver. Function gradually returns from the proximal muscle groups to the distal muscle groups.

The severity of the injury correlates with the underlying pathophysiology. Neuropraxia is a selective demyelination of the nerve sheath, and it is the most benign injury. Axonotmesis is a disruption of the axon and the myelin sheath, but the epineurium is intact. The most severe injury is a neurotmesis or a complete disruption of the endoneurium. This injury is associated with the most unfavorable prognosis.

The differential diagnoses of burners include acute cervical disk herniations, foraminal stenosis, and extradural intraspinal masses.

Stingers are thought to be the result of either of the following mechanisms:

- A distraction or stretch injury in which the head is driven to the side opposite the painful arm and the ipsilateral shoulder is depressed. This causes a momentary stretch injury to the upper cords of the brachial plexus.
- The extended C-spine is compressed and rotated toward the painful arm. Injury occurs because the cervical nerves are tethered by fibrous tissue between the vertebral arteries and the distal foramina at each cervical level. These dentate ligament attachments become taut and stretch the cervical nerve roots as they leave the spine.

Because most burners are self-limited, the most important treatment obligation of the team physician is to rule out an unstable cervical injury. The key to assessment is that patients with burners have full pain-free neck range of motion (ROM). If neck motion is decreased or painful, withdraw the athlete from play and obtain cervical radiographs to rule out fracture/dislocation. If symptoms persist for 3-4 weeks following injury, obtain an electromyogram (EMG) to evaluate upper trunk function.¹⁴

Acute Cervical Sprains/Strains & Intervertebral Disk Injuries

Acute cervical sprains/strains

A sprain is defined as an injury to the paraspinal musculotendinous unit. A strain is defined as an injury of the paraspinal muscle itself. An athlete with a sprain or strain usually presents after jamming his/her neck. The pain is localized to the C-spine and limits cervical ROM. Pain and paresthesias do not radiate to the arms. The neural examination is normal, and radiographs are negative for evidence of fracture or dislocation.

Take the player through a series of movements to evaluate the ROM. If the patient has full ROM with no radiation of pain, no paresthesias, and a normal neurologic examination, treat with nonsteroidal anti-inflammatory

medications and a soft cervical collar (C-collar) for comfort. Once the pain has resolved, the athlete can return to activity. If the player has limited ROM, protect the neck and remove him or her from activity.

Obtain a radiographic series to include anteroposterior (AP) and lateral flexion/extension views. If a fracture or dislocation is encountered, institute proper immobilization and stabilization. If these radiographs are negative but symptoms persist, obtain an MRI to rule out disk herniation.

Intervertebral disk injuries

Acute disk herniations in football are rare. However, with the acute onset of transient neurologic deficits and negative cervical radiographs, the possibility of a ruptured cervical disk must be considered. Symptoms of herniation vary from radiculopathy to anterior cord syndrome. Anterior cord syndrome occurs with an acute paralysis of the upper, lower, or all 4 extremities. An associated loss of pain and temperature sensation to the level of the lesion occurs.¹⁵ The posterior column vibratory, proprioceptive, and light touch sensations are preserved.

A high degree of clinical suspicion is necessary to avoid missing the diagnosis of a disk injury. If disk injury is suggested, confirm the diagnosis with a CT myelogram or an MRI (see Images 1-4). Once the diagnosis of acute disk herniation with neurologic symptoms is made, an anterior discectomy with interbody fusion may be necessary.

In contrast to the rare nature of acute disk herniations in contact sports, disk injuries without frank herniation or neurologic injury can be common and are characterized by chronic changes. Chronic disk changes frequently are seen in athletes who compete in contact sports. Albright studied cervical spine radiographs of 75 University of Iowa freshmen football recruits.¹⁶ The radiographs were obtained after the individuals played high school football but before they played college football. Albright found that 32% had 1 or more of the following conditions:

- Occult fracture
- Vertebral compression fracture
- Disk space narrowing
- Osteophytes and degenerative changes

Albright's findings illustrate that the constant loading of the C-spine in contact sports leads to chronic degeneration. MRI scans of patients with chronic disk injuries reveal a disk bulge with no obvious herniation. Treatment of these patients is conservative, and contact activity should be withheld until the athlete has regained a painless full ROM of the C-spine.

Cervical Fracture/Dislocations

Cervical fractures and dislocations occur when the axial loading forces applied to the C-spine are greater than the yield strength of the vertebral bodies or the supporting ligamentous structures. A spectrum of pathology exists, including the following:

- Subluxation without fracture, with or without neurologic injury
- Dislocations, with or without neurologic injury
- Fractures, with or without neurologic injury

The most important consideration when discussing cervical fractures and dislocations is the concept of stability. Stability, as described by White et al, is the ability of the spine to limit its patterns of displacement during physiologic loads to prevent damage or irritation to the spinal cord and nerve roots.¹⁷ Instability of the adult spine therefore is defined as dysfunction of the posterior elements with more than 3.5 mm displacement (or >20% translation) in the horizontal sagittal plane. See Image 28.

Instability is also apparent by analyzing the angular measurements between motion segments. Greater than 20° of sagittal plane rotation on flexion/extension films is considered abnormal and potentially unstable. In the acute

setting where flexion/extension radiographs are not obtainable, greater than 11° of relative sagittal plane angulation between cervical motion segments on a static lateral C-spine radiograph is considered unstable. See Image 29.

White and Panjabi's work on cervical instability culminated in the creation of a scoring checklist to serve as an algorithm and an objective assessment of instability. This checklist is illustrated in the White and Panjabi Scoring Cervical Instability Table in Image 27.

Patients are assessed anatomically, radiographically, neurologically, and physiologically. The patient is graded on each of these criteria, and the grades are added to obtain the final score. A total score of 5 or more is indicative of a patient with an unstable spine.

Subluxation or dislocation without fracture results from disruption of the posterior soft tissue supporting elements. Angulation and anterior translation of the superior vertebrae occurs. No associated fractures exist, and associated neurologic injuries may or may not exist. The diagnosis is made by flexion/extension lateral C-spine radiographs, which show active motion, anterior intervertebral disk space narrowing, and fanning of the spinous processes posteriorly. Obtaining the flexion/extension radiographs in the presence of the treating spine surgeon and in a patient who is awake and communicative is imperative (see Images 5-10).

An alternative to the flexion/extension radiographs is the use of controlled axial-traction lateral radiographs, also referred to by White as the "stretch test."¹⁸ The stretch test is performed after a standard nontraction lateral C-spine radiograph has been obtained and examined to rule out obvious instability or subluxation.

In the stretch test, the patient is placed supine with the head supported on a roller platform to reduce friction. The head is placed in a traction rig with either Garner-Wells tongs or a head halter, and incremental 10-lb loads of weight are applied. The 10-lb weights are added in the presence of the treating physician. The maximum weight allowed is equivalent to 33% of the patient's body weight.

The physician performs serial neurologic assessments of the patient with each addition of weight. A lateral C-spine radiograph is obtained with each addition of weight. The time interval between weight increments should be at least 5 minutes. The stretch test is considered positive for instability if one of the following situations occurs: (1) the patient sustains a change in neurologic function, (2) on comparison with the pretraction radiograph, there is greater than 1.7 mm of interspace separation of the anterior or posterior elements, or (3) there is greater than 7.5° change in the angle between vertebrae.

The prognosis in patients with subluxation without fracture depends on the degree of displacement. Instability is likely despite nonoperative treatment, and if anterior subluxation is more than 20% of the vertebral body width, treatment should be posterior cervical fusion.

Atlantooccipital dislocations (see Image 11) result from high-speed collisions and have never been reported in football. They are described as complete injuries. These injuries usually are fatal secondary to complete respiratory arrest. When this injury is suspected, cervical traction is contraindicated. If the patient survives the injury, treatment is to align the spine and place the patient in a halo vest until C0-C2 fusion can be performed.

A traumatic rupture of the transverse ligament of the atlas (see Images 12-13) leads to widening of the atlantodens interval and decreased space for the spinal cord.

C1 or atlas fractures

C1 or atlas fractures (see Images 14-15) usually result from axial loading and are decompressive fractures that rarely result in neurologic deficits. They can be classified as follows:

- Anterior arch fractures
- Posterior arch fractures
- Lateral mass fractures
- Jefferson (burst) fractures

All C1 or atlas fractures can be treated with halo vest immobilization until fracture healing occurs.

Odontoid fractures

The 3 types of odontoid fractures are as follows:

- Type I
 - Type I odontoid fractures are cephalad to the transverse ligament and are secondary to avulsion of alar ligaments.
 - They rarely are associated with neurologic injury or C1-C2 instability.
 - Stability can be assessed with lateral flexion/extension views.
 - Most type I odontoid fractures can be treated with a C-collar.
- Type II
 - Type II odontoid fractures (see Image 16) are through the neck of the odontoid process.
 - These fractures usually are secondary to hyperextension, flexion, or rotational forces.
 - The overall union rate of type II fractures is 68% with halo treatment. Type II odontoid fractures with more than 10° of angulation or more than 5 mm of translation should be treated with surgery rather than a halo to decrease the pseudoarthrosis rate.
 - Nonunions can be common among type II odontoid fractures. In patients with significant risk factors, primary C1-C2 fusion by a variety of techniques should be employed. Patients with low risk factors for nonunion can be treated with reduction and halo immobilization for 12 weeks. The risk factors for nonunions include the following:
 - Age older than 50 years
 - Displacement of more than 5 mm
 - Posterior versus anterior displacement
 - Excessive halo vest treatment
- Type III
 - Type III odontoid fractures (see Images 17-18) extend into the cancellous bone of the body of C2 and therefore have a high rate of union.
 - These fractures usually can be treated with halo immobilization for 12 weeks.
 - If the fracture is impacted and has a stable pattern, treatment with a rigid C-collar in a compliant patient for 12 weeks can be an option.

Traumatic spondylolistheses of C2

Traumatic spondylolistheses of C2 also can occur. These fractures also are known as hangman's fractures. They usually are diagnosed on lateral C-spine radiographs. Neurologic injury usually does not occur unless a C2-C3 facet dislocation is present. The 4 types of traumatic spondylolistheses of C2 are as follows:

- Type I
 - A type I hangman's fracture (see Image 19) is either nondisplaced or has less than 3 mm of C2-C3 translation.
 - No angulation of the fracture fragments exists.
 - The injury occurs secondary to a combined hyperextension/axillary compression force.
 - This type of fracture usually can be treated with a C-collar for 3 months.
- Type II
 - These fractures are associated with significant translation of more than 3 mm with angulation.
 - These injuries are secondary to initial hyperextension-loading forces, followed by combined flexion/compression forces.
 - Treatment for type II injuries depends on the amount of initial translation, as follows:
 - For 3-6 mm of initial translation, treat with a halo vest for 3 months.
 - For more than 6 mm of translation, treat with 4-6 weeks of halo traction, followed by halo vest immobilization for 3 months.
- Type IIA

- This injury also is known as the Starr-Eismont variant (see Image 20) and is associated with significant angulation and minimal translation.
- Traction in these injuries is contraindicated because it leads to significant translation and associated neurologic injury.
- Treatment includes immediate halo vest with mild axial compression for reduction.
- Type III
 - These injuries are associated with severe angulation and translation.
 - Unilateral or bilateral facet dislocations usually accompany them.
 - The mechanism of injury is a combined flexion/compression force.
 - Closed reduction is exceedingly difficult. Open reduction and internal stabilization usually is required.

Injuries of the subaxial cervical spine generally are associated with an increased likelihood of neural compression due to a decreasing ratio of canal diameter to cord diameter.

Types of injuries

- Avulsion fractures
 - The spinous process is the usual location of avulsion fractures.
 - When these fractures occur at C7 (see Image 21), they are termed clay shoveler's fractures. This injury results from forceful contraction of trapezius and rhomboid muscles or from a sudden severe flexion force transmitted to posterior spinous ligaments.
 - Treat with a C-collar for comfort.
- Compression fractures
 - Compression fractures are defined as the vertebral body having an intact middle column and loss of anterior body height.
 - Evaluate compression fractures with flexion and extension radiographs, CT scan, and MRI scan.
 - Treatment depends on the degree of anterior compression, as follows:
 - If there is less than 25% anterior compression, treat the patient with a C-collar.
 - If there is more than 50% anterior compression, patients often have posterior ligamentous failure, which results in significant instability that requires posterior fusion with or without anterior column reconstruction. Images 22-23 show the lateral radiograph and axial CT scans of a patient with a C5 compression fracture.
- Facet joint injuries
 - These subluxations and dislocations (see Images 5-10) occur as a result of disruption of the supraspinous ligaments, interspinous ligaments, ligamentum flavum, and facet capsule.
 - Facet joint injuries can be unilateral or bilateral, and neurologic injury varies.
 - Lateral radiographs help the physician confirm the diagnosis. CT scan helps rule out bony involvement, and MRI delineates associated disk herniations.
 - The mechanism of injury corresponds to whether the lesion is unilateral or bilateral. Unilateral lesions are the result of flexion and rotation with axial force. Bilateral lesions are the result of severe flexion with axial loading.
 - Treatment is controversial because of the risk of further neurologic injury from further disk herniation with the reduction maneuver. The goals of treatment are as follows:
 - Prevent further neurologic injury
 - Reduce the subluxation/dislocation
 - Stabilize the spine in the reduced position
 - The focus of controversy is the question of whether to obtain an MRI before performing a closed reduction of the subluxation or dislocation.
 - Eismont and others have recommended an MRI prior to reducing a subluxation to rule out a herniated nucleus pulposus that could further herniate during the reduction and result in catastrophic cord sequelae.¹⁹

- Cotler and others believe that high-weight rapid reduction should be performed as soon as possible and that the MRI should be performed following the reduction.
 - Vaccaro et al have shown in a prospective study of 11 patients with cervical dislocations who had prereluction and postreluction MRI scans that disk herniations were identified in 2 of the 11 patients before reluction.²⁰ They performed awake closed reluction by high-weight rapid traction. Reluction was successful in 9 of the 11 patients. Of the 9 patients with successful closed reluction, 2 had disk herniations before reluction and 5 more had disk herniations on the postreluction MRI. None of the patients had neurologic worsening after reluction. Cotler and Vaccaro therefore conclude that an MRI can be done after the subluxation or dislocation is reluced to assess the cord and disk. In cases of acute paraplegia, the moments saved can be cord saving.
 - Eismont agrees with this last point in patients with complete distal motor loss, with or without distal sensation (Frankel Grades A and B), as these patients have the most to gain and least to lose by rapid reluction and the possible associated risks. Eismont does not agree in the circumstance of a patient who is neurologically intact or near normal (Frankel Grade D and E), as these patients have the greatest to lose in the event of further disk herniation with closed reluction leading to paralysis.¹⁹
 - Eismont recommends provisional immobilization with a rigid C-collar, 10 lb of skull traction, and an MRI before reluction is attempted. If no disk herniation is detected, perform reluction with skeletal traction of 5-7 lb/level, up to a maximum of 50 lb. Closely monitor radiographic results and neurologic function during the reluction. Once the reluction is obtained, posterior fusion should be performed if there is no associated disk herniation. If a disk is encountered on the prereluction MRI, Eismont recommends an anterior cervical discectomy, reluction, and plate fixation.¹⁹
- Vertebral burst fractures
 - Cervical burst fractures result from severe axial loading in combination with hyperflexion forces.
 - Burst fractures include a comminuted fracture of the middle spinal column, and if destabilized posteriorly, they can result in kyphosis.
 - Cord injury usually is present because of retropulsion of fracture fragments.
 - Perform a radiographic series, a CT scan, and an MRI to evaluate severity of neural compression, intramedullary cord injury, and ligamentous damage.
 - Employ skeletal traction for spinal realignment and decompression of the canal by ligamentotaxis of retropulsed fragments.
 - Perform an MRI with the patient in traction to assess the severity of canal compromise postreluction.
 - In patients with canal compromise and neural defects, perform an anterior decompression and reconstruction with strut graft and plate fixation. If unstable (ie, a 3-column lesion), the patient may require an anterior and posterior fusion/stabilization.
- Teardrop fractures
 - Teardrop fractures (see Images 24-25) result from severe flexion-axial loading forces and are 3-column injuries.
 - They are characterized by (1) a displaced fracture of the anteroinferior corner of the superior body, (2) segmental disk disruption, (3) posterior ligamentous injury, and (4) retropulsion of the proximal body into the neural canal.
 - Radiographically, retrolisthesis of the posteroinferior portion of the involved body often results in neural compression with deficits ranging from nerve root injuries to complete spinal cord injuries.
 - Diagnostics and treatment are the same as for burst fractures.

Risk for further injury

The issue of returning to play after a patient sustains a C-spine injury should be based on the risk for further injury, as follows:

- Conditions with a slightly increased risk of reinjury following the initial insult include the following:
 - Asymptomatic bone spurs
 - Healed nondisplaced fractures
 - Stingers/burners
 - Healed disk herniations
 - Healed laminar fractures
 - Asymptomatic foraminal stenosis
- Moderate risk conditions that are associated with a significant chance for recurrence of symptoms and an increased risk for permanent injury include the following:
 - Facet fractures
 - Lateral mass fractures
 - Nondisplaced healed odontoid fractures
 - Nondisplaced healed C1 ring fractures
 - Acute lateral disk herniations
 - Cervical radiculopathy secondary to foraminal spur
- Extreme risk conditions that have the highest risk of recurrence and of permanent damage include the following:
 - Os odontoideum
 - Ruptured transverse ligament of C1-2
 - Occipitocervical dislocation
 - Displaced odontoid fractures
 - Unstable fracture dislocations
 - Cervical cord anomalies
 - Acute central disk herniations

Cervical Spinal Stenosis

Cervical spinal stenosis is defined as the diminution of the anteroposterior diameter of the spinal canal, either as an isolated congenital observation or with disk herniation, degenerative changes, or posttraumatic instability.²¹

Methods of measuring the degree of spinal stenosis continue to evolve with the evolution of imaging technologies. In 1956, Wolfe et al described measuring the space for the cord on plain lateral C-spine radiographs by measuring the distance from the middle of the posterior surface of the vertebral body to the most anterior point on the spinolaminar line for vertebrae C3-7. The normal range was 14.2-23 mm. A measurement of less than 13 mm was considered stenosis. Values obtained by measurement on the lateral plain radiographs could be skewed because of radiographic magnification or variations in radiographic techniques. The actual size of the canal is better assessed by CT scan.

To compensate for these variances in radiographic techniques, Torg and Pavlov described the Torg/Pavlov ratio.²² This ratio is a measurement of the width of a given vertebral body on the lateral C-spine radiograph divided by the corresponding space allowed for the cord at the same level (see Image 26). A value of less than 0.8 was considered to be cervical stenosis and a serious risk factor for neurologic injury in contact sports.

Herzog illustrated that the Torg/Pavlov ratio may have resulted in false-positive indications.²³ Herzog reviewed the CT scans of football players with abnormal Torg/Pavlov ratios and found that 70% of players with abnormally small Torg/Pavlov ratios had normal-sized cervical spinal canals.²³ These findings are explained by the fact that football players have abnormally large vertebral bodies. This fact makes the denominator in the Torg/Pavlov ratio larger, and the ratio value is artificially decreased, resulting in a false positive. Additionally, Herzog found no correlation between a Torg/Pavlov ratio of 0.8 and any transient neuropraxia or permanent neurologic deficits. Castro et al, in the *American Journal of Sports Medicine*, illustrated that cord diameter also varies, and it is the relative difference between the canal size and the cord diameter that creates the clinical condition of stenosis.

Epstein concluded that the presence of a stenotic canal influenced the morbidity and prognosis of a spinal cord injury and that patients with the smallest anterior-posterior canal diameter had the most severe myelopathy

following injury.²⁴ Eismont et al echoed Epstein's conclusions when they looked at 98 patients with C-spine fractures and/or dislocations and found that the sagittal size of the cervical canal correlated with the extent of neurologic injury.²⁵ They concurred that patients with small diameter canals had more significant neurologic sequelae. Matsura et al found a correlation between the shape of the spinal canal, the central canal diameter, and the predisposition to spinal cord injury.

Cantu advocates the functional definition of spinal stenosis.²⁶ Functional spinal stenosis is present when the size of the canal is so small that the protective spinal fluid cushion around the cord is obliterated or when the cord is deformed on CT myelogram or MRI. Any athlete with functional cervical stenosis is at increased risk for quadriplegia and should be prohibited from participating in contact sports.

Return To Play

To help establish objective guidelines for return to play following an injury, Watkins et al proposed a point grading system to quantify the patient's clinical situation.²⁷ This grading system was meant as a guideline for return to play. The physician must consider the entire scenario for each individual player. Watkins et al looked at the following 3 topics and assigned point values according to the player's condition, as follows:

- Extent of the neurologic injury
 - 1 point - Unilateral arm numbness or dysesthesias or loss of strength
 - 2 points - Bilateral arm loss of motor or sensory function
 - 3 points - Ipsilateral arm and leg symptoms
 - 4 points - Transitory quadriparesis
 - 5 points - Transitory quadriplegia
- The time from injury to treatment
 - 1 point - Less than 5 minutes
 - 2 points - Less than 1 hour
 - 3 points - Less than 24 hours
 - 4 points - Less than 1 week
 - 5 points - More than 1 week
- The narrowing of the central canal diameter
 - 1 point - More than 12 mm
 - 2 points - Between 12 and 10 mm
 - 3 points - 10 mm
 - 4 points - Between 10 and 8 mm
 - 5 points - Less than 8 mm

The points tabulated from each of the 3 categories then are added together and compared to the following scoring scale:

- 0-6 points - Minimal risk associated with return to play
- 6-10 points - Moderate risk associated with return to play
- 10-15 points - Severe risk associated with return to play

These criteria serve as a guide for the team physician; however, the physician should consider each case individually and request the appropriate consultations as needed.²⁸

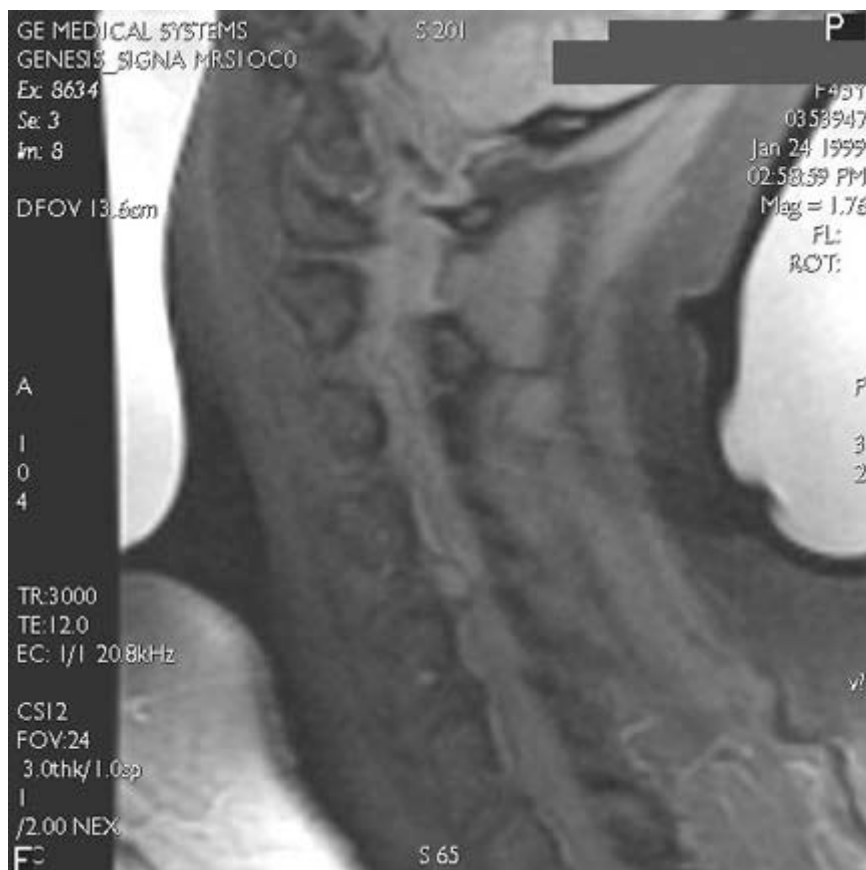Conclusion

The incidence of catastrophic cervical injuries in sports has significantly decreased over the last 30 years. This decrease is the result of monumental rule changes, such as the ban on spearing in American football, better coaching on contact and tackling techniques, the presence and instruction of athletic trainers at all levels of play, and the improvement in protective gear including helmets and shoulder pads. Unfortunately, when catastrophic neurologic injuries do occur, they are permanent and life changing. The team physician plays a crucial role in the

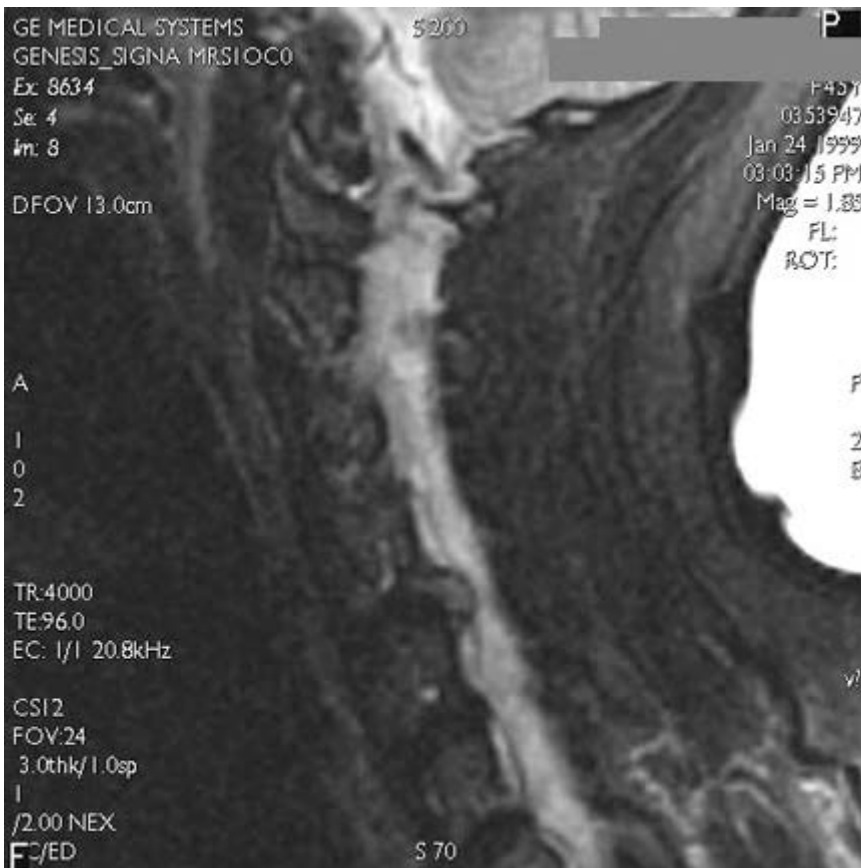
coordination of medical assessment on the playing field, immobilization and transportation to a qualified facility for evaluation and treatment, and decision making regarding return to play following an injury. These decisions should be discussed with the athlete and the athlete's parents, coaches, trainers, and agents. The ultimate decision should be made in the best interest of the patient.²⁹

For excellent patient education resources, visit eMedicine's Back, Ribs, Neck, and Head Center. Also, see eMedicine's patient education article Whiplash.

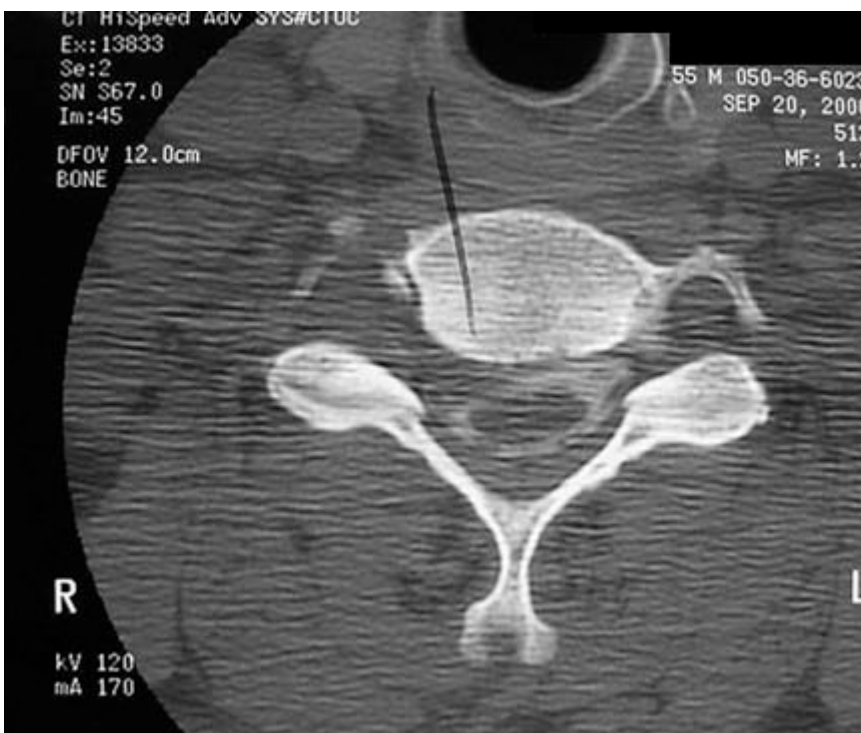Multimedia



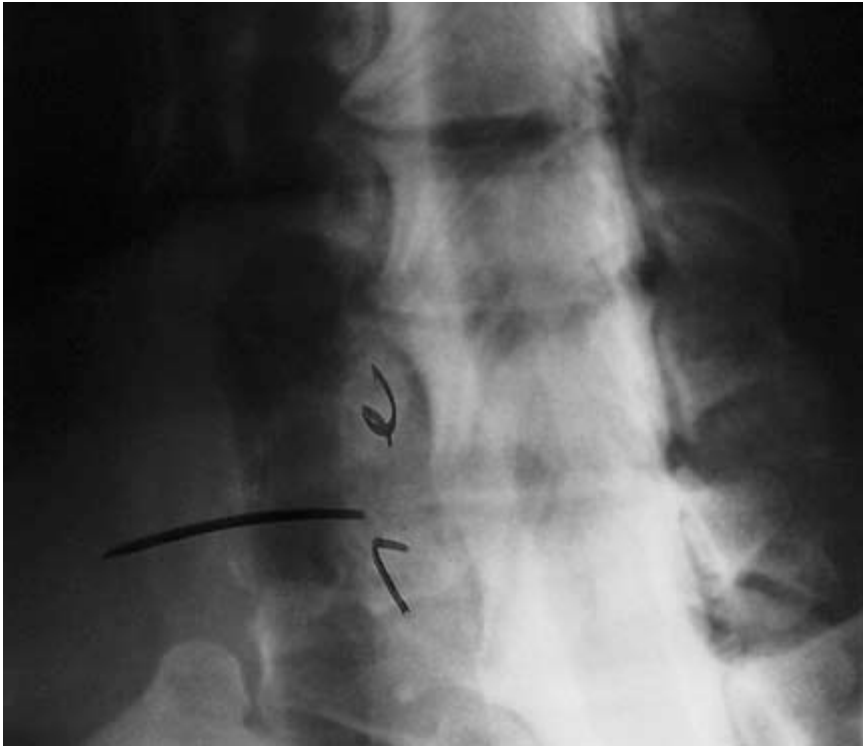
Media file 1: T1-weighted MRI of a cervical disk herniation.



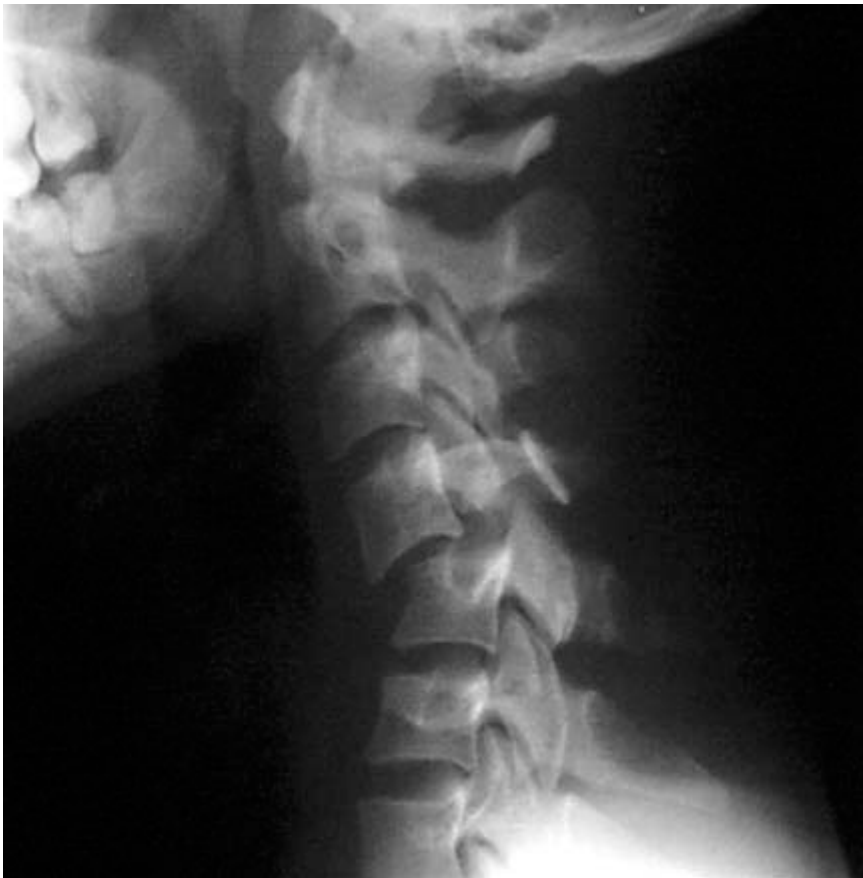Media file 2: T2-weighted MRI of cervical disk herniation.



Media file 3: Axial CT scan of cervical herniated nucleus pulposus.



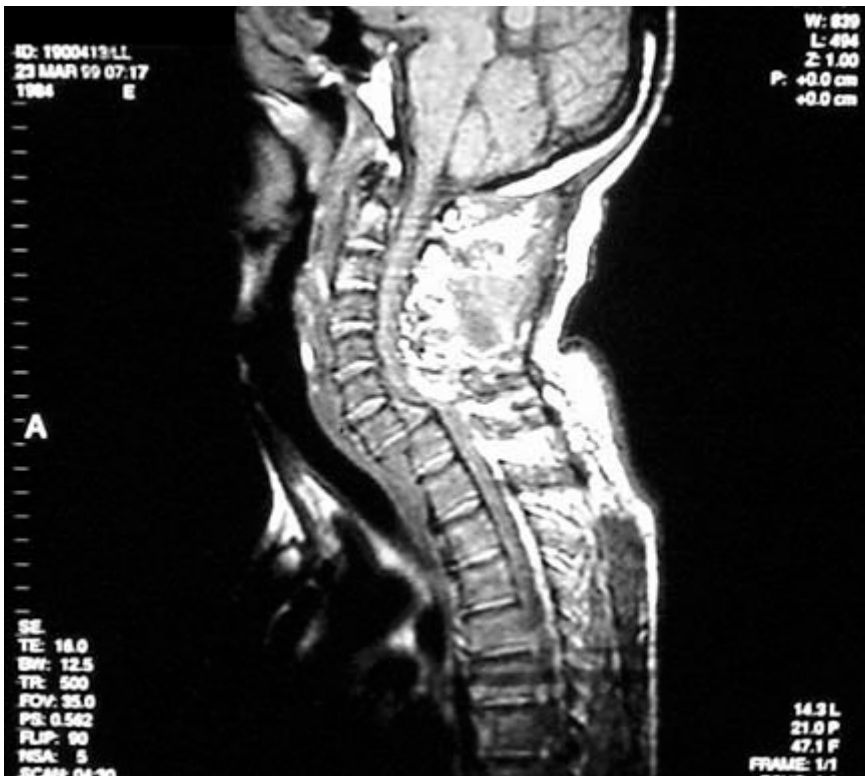Media file 4: Myelogram of cervical herniated disk. A filling defect is shown.



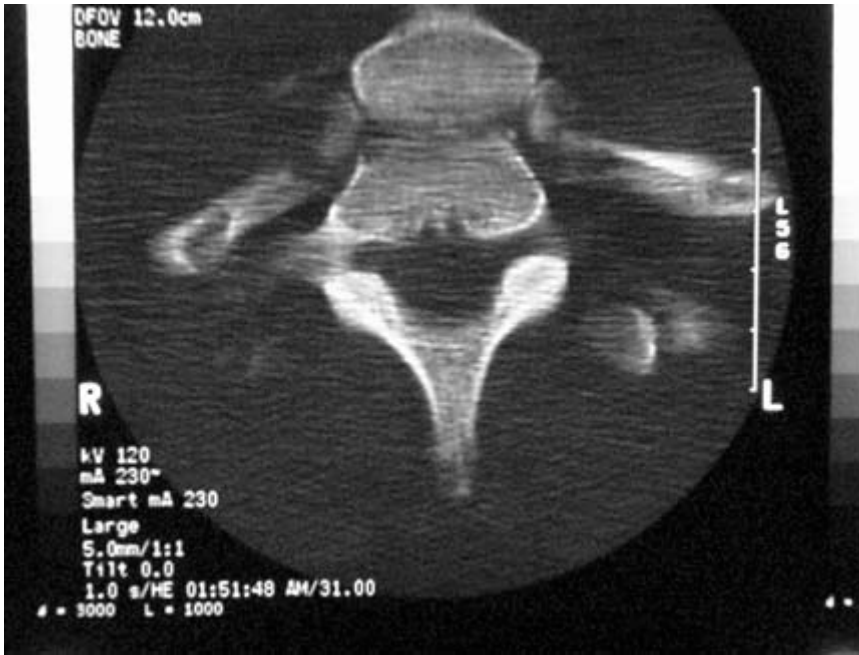Media file 5: Plain radiograph of jumped facets of C4 on C5.



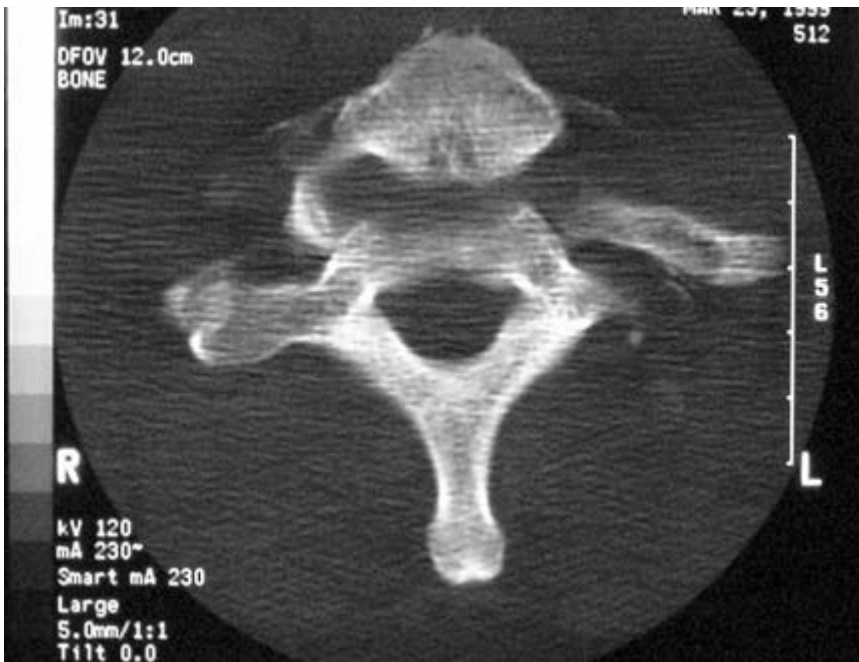Media file 6: Sagittal CT scan of jumped facet.



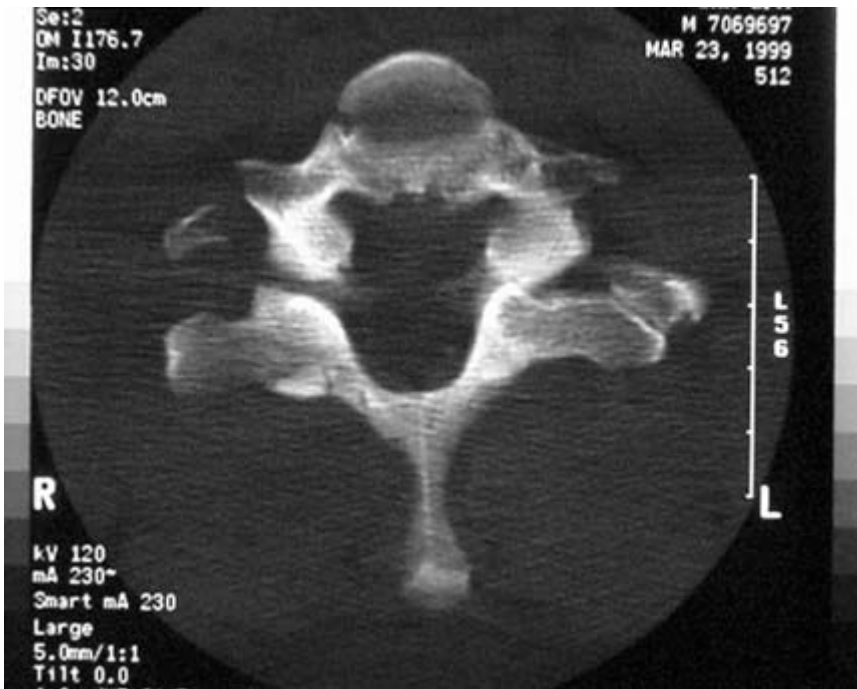Media file 7: Sagittal MRI of facet dislocation of C7 on T1.



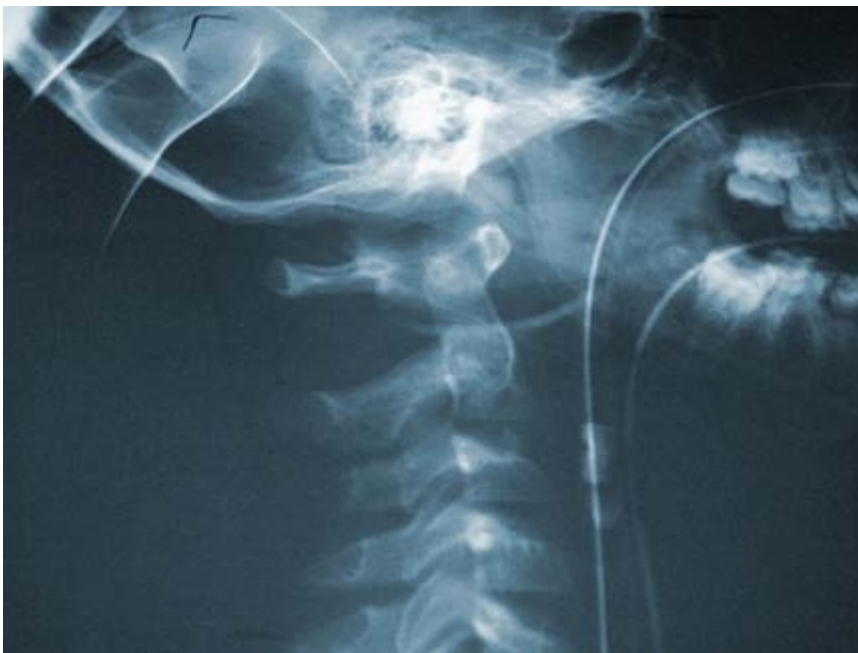Media file 8: Jumped facets.



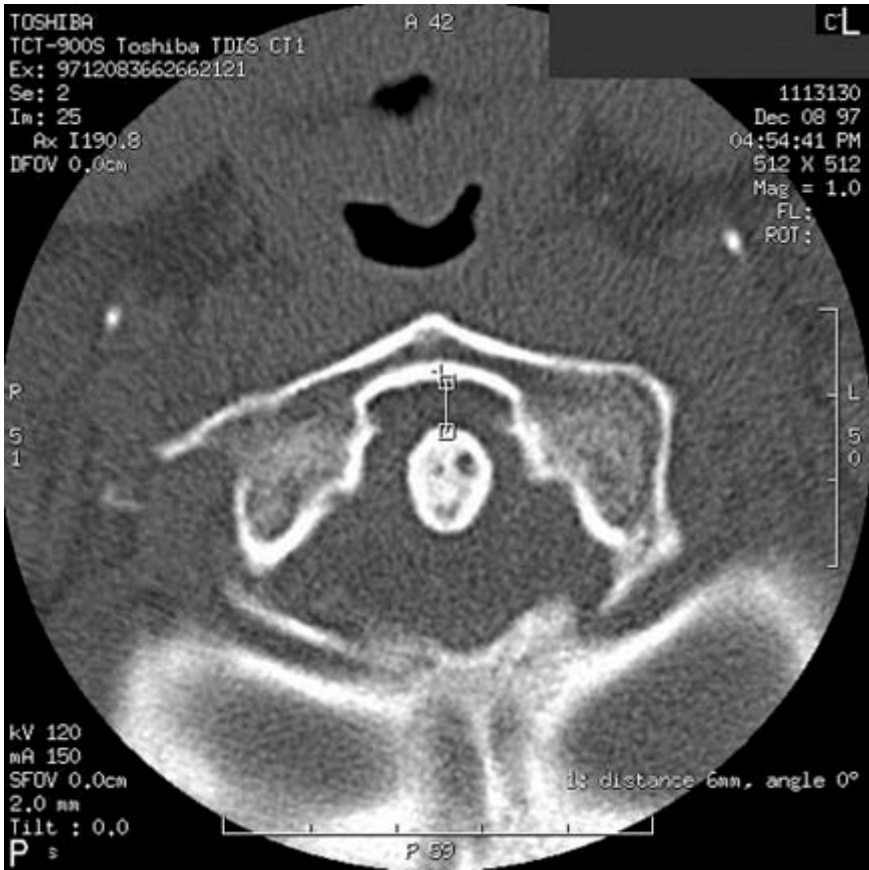
Media file 9: Jumped facet showing anterior displacement of one vertebra on the adjacent inferior vertebrae.



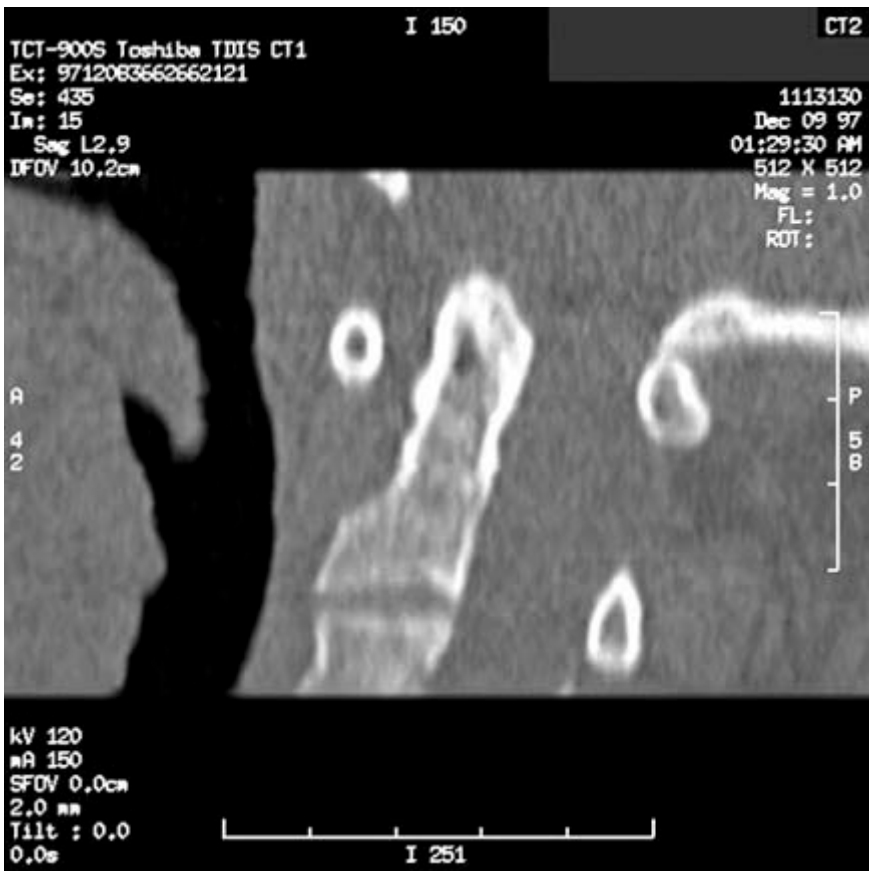
Media file 10: Jumped facets with complete anterior displacement of the proximal vertebrae.



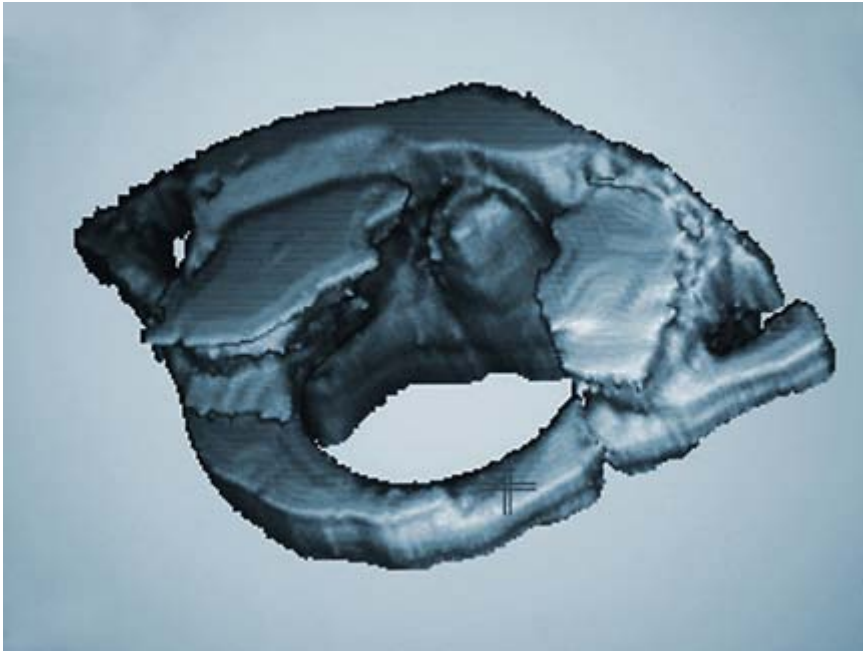
Media file 11: Atlantooccipital dislocation.



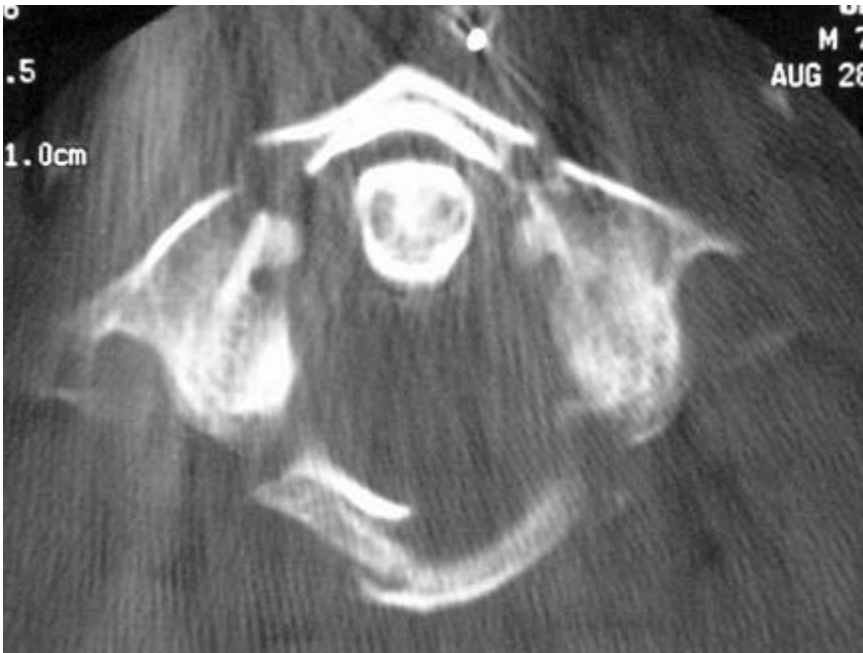
Media file 12: Axial CT scan of an increased atlantodens interval.



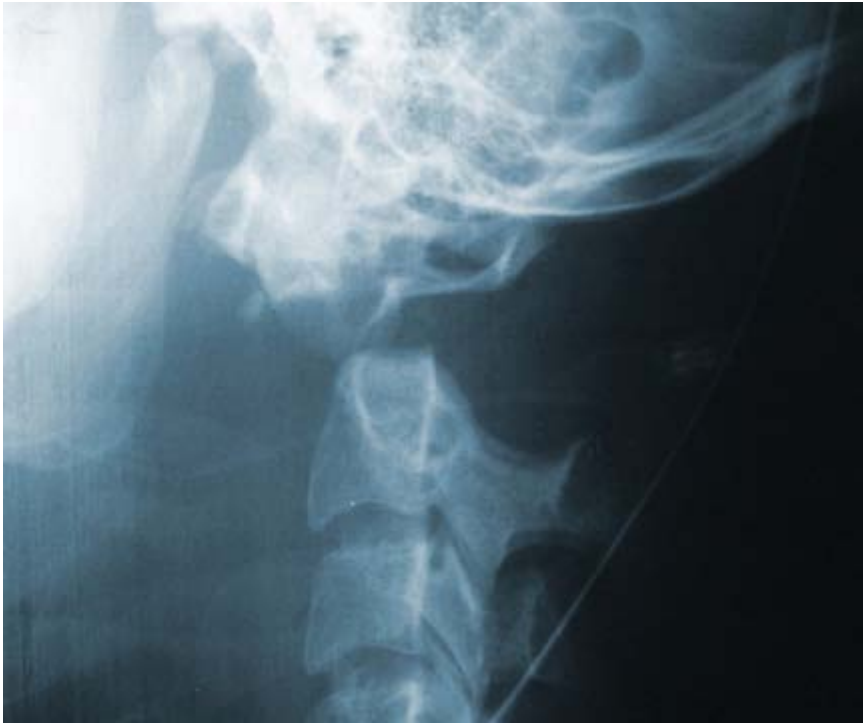Media file 13: Sagittal CT scan reconstruction that shows widening of the atlantodens interval.



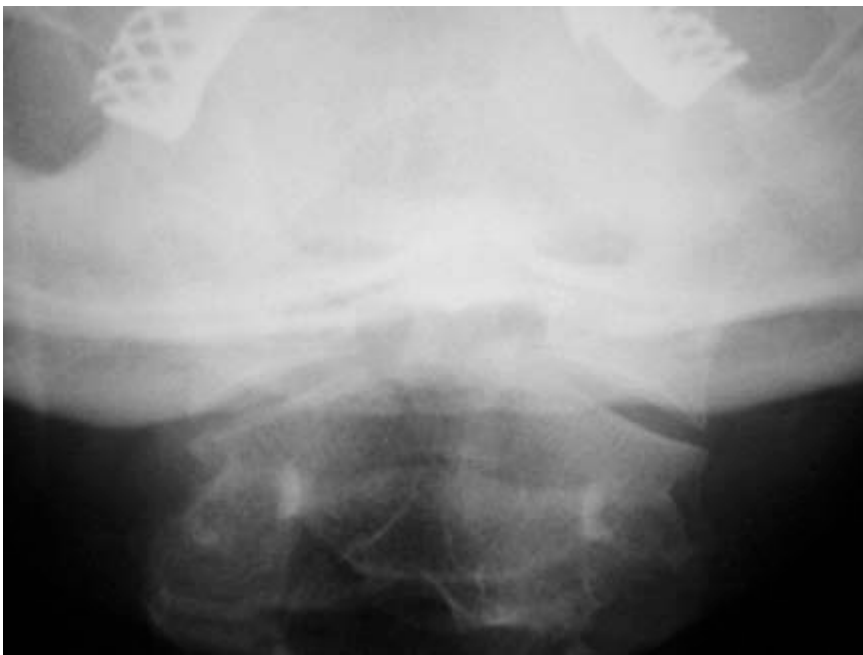Media file 14: Three-dimensional CT scan of C1.



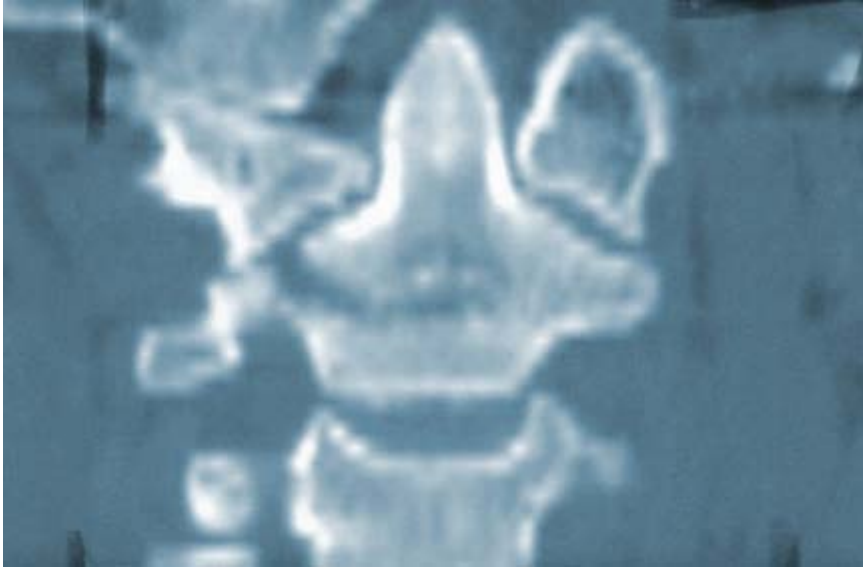
Media file 15: Axial CT scan of a Jefferson fracture.



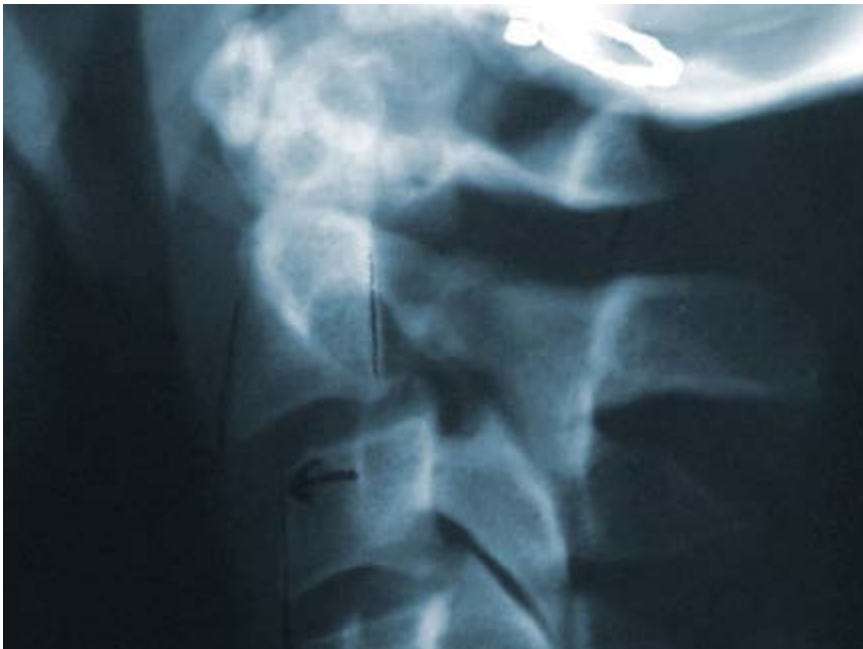Media file 16: Displaced type II odontoid fracture.



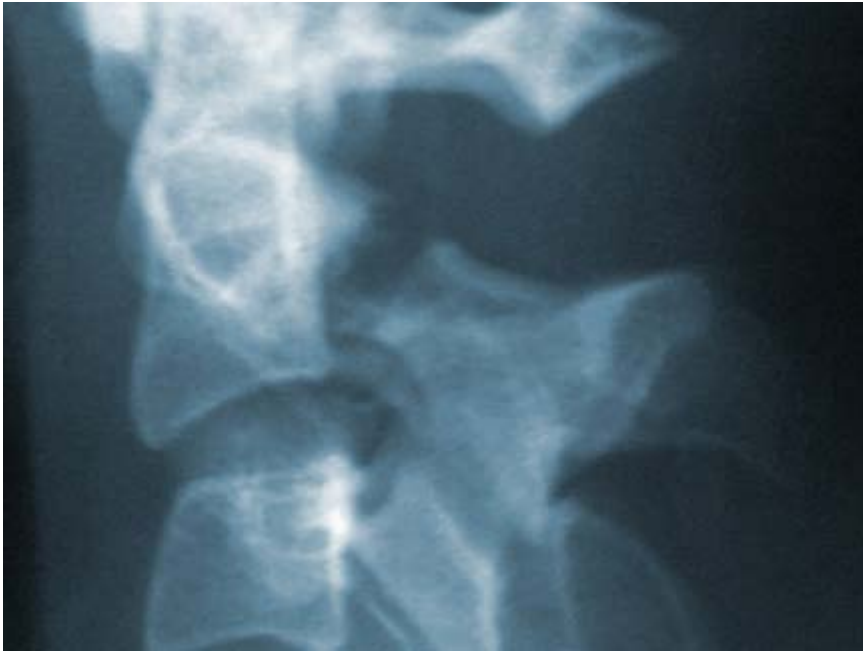Media file 17: Anteroposterior view of type III odontoid fracture.



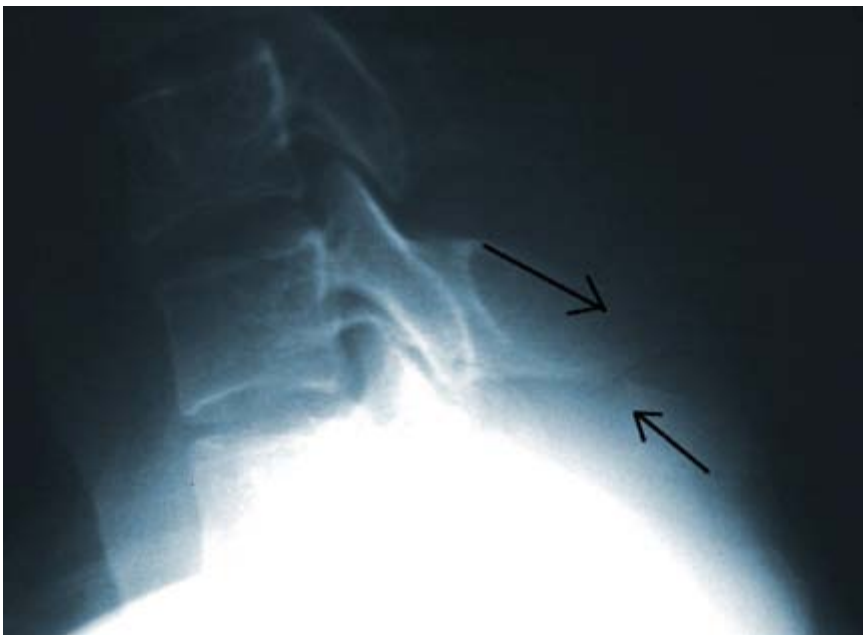
Media file 18: Coronal CT scan of type III odontoid fracture.



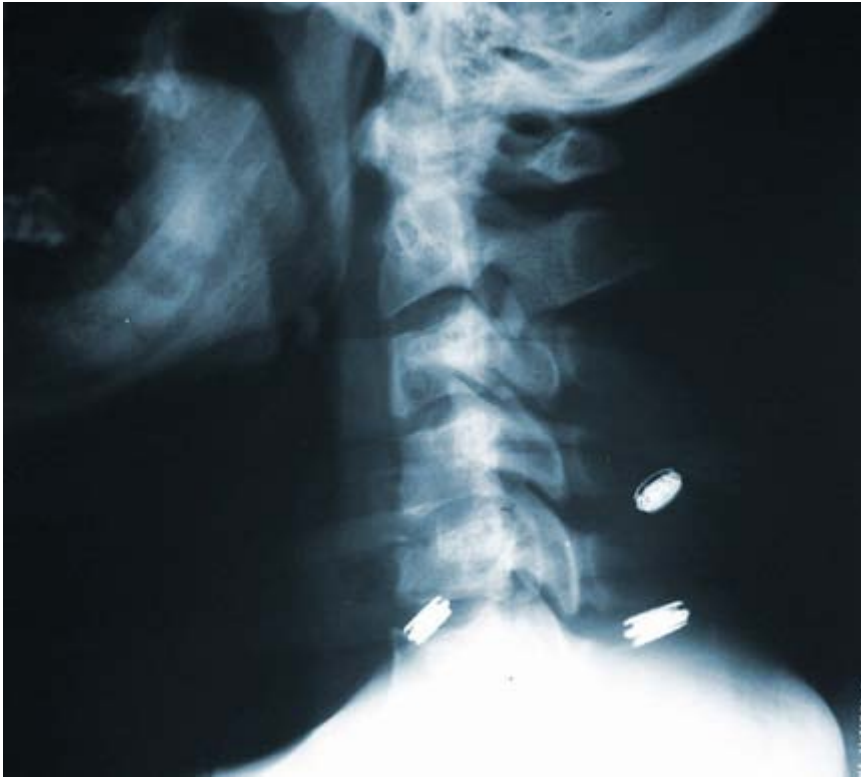Media file 19: Type I C2 traumatic spondylolisthesis. Note the anterior translation but lack of angulation.



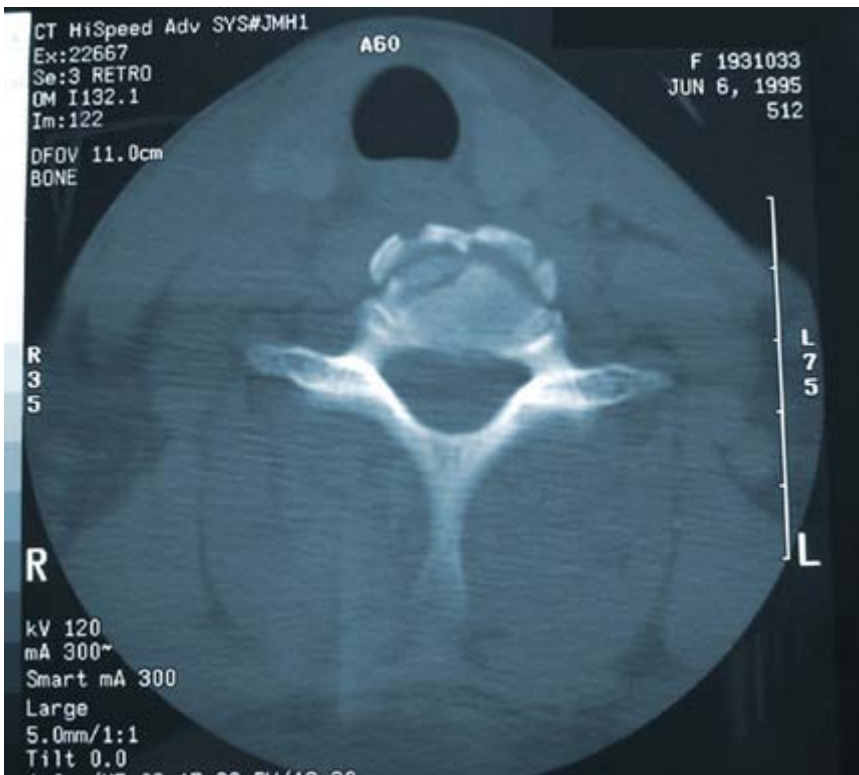Media file 20: Close-up lateral radiograph of type IIA (Starr-Eismont variant) C2 traumatic spondylolisthesis. Note the significant angulation with minimal translation.



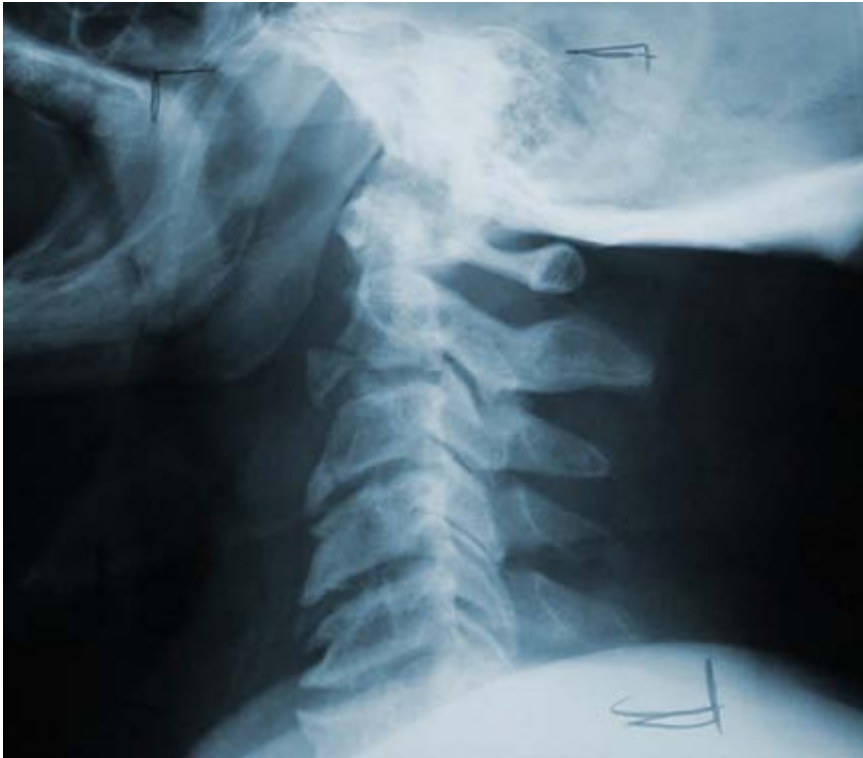Media file 21: Avulsion fracture of C7 (the clay shoveler's fracture).



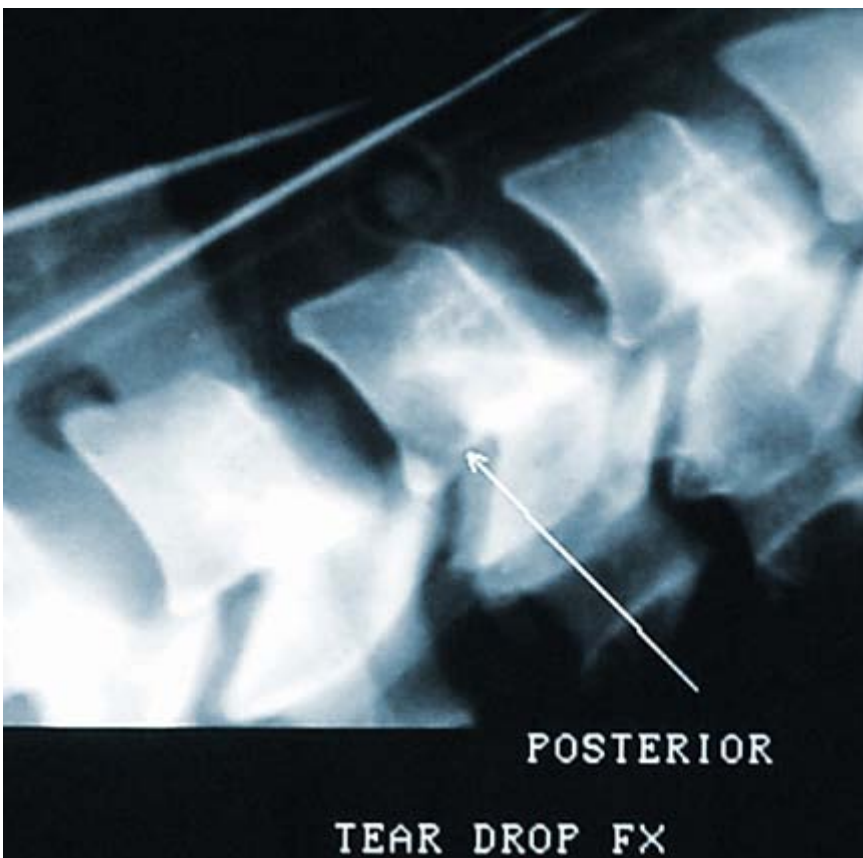
Media file 22: C5 compression fracture.



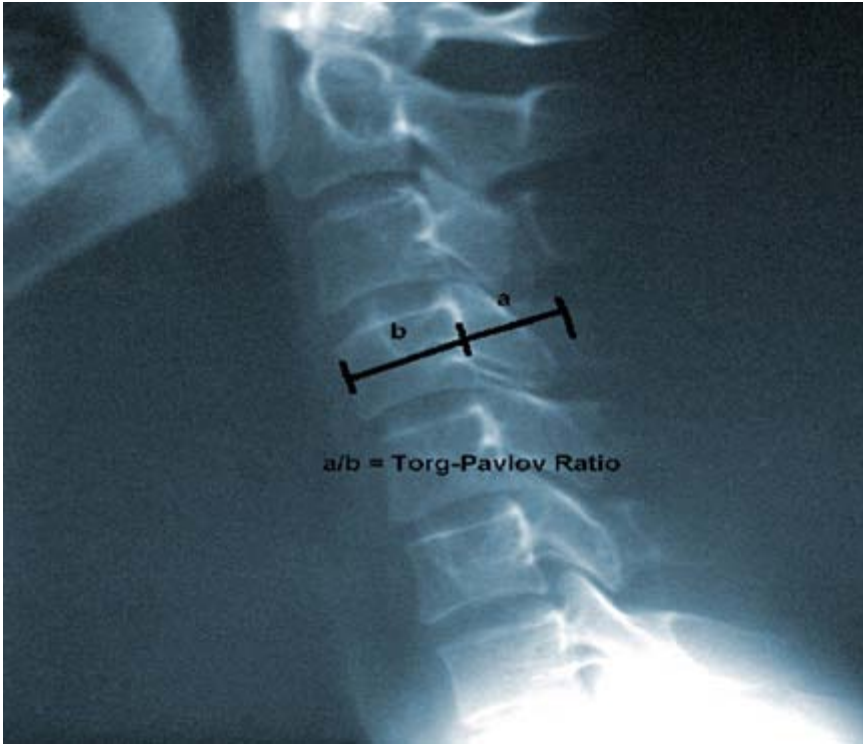Media file 23: Axial CT scan of C5 compression fracture. Intact middle and posterior columns are shown.



Media file 24: Teardrop fracture.



Media file 25: Posterior teardrop fracture.



Media file 26: Lateral cervical spine plain radiograph illustrating the Torg/Pavlov ratio.

Checklist for the Diagnosis of Instability in the Middle and Lower Cervical

Element

Anterior elements destroyed or unable
to function

Posterior elements destroyed or unable
to function

Positive stretch test

Radiographic criteria*

A. Flexion/extension x-rays

1. Sagittal plane translation > 3.5 mm
20% (2 pts)
2. Sagittal plane rotation $> 20^\circ$ (2 pts)

OR

B. Resting x-rays

1. Sagittal plane displacement > 3.5 mm
20% (2 pts)
2. Relative sagittal plane angulation $> 10^\circ$
(2 pts)

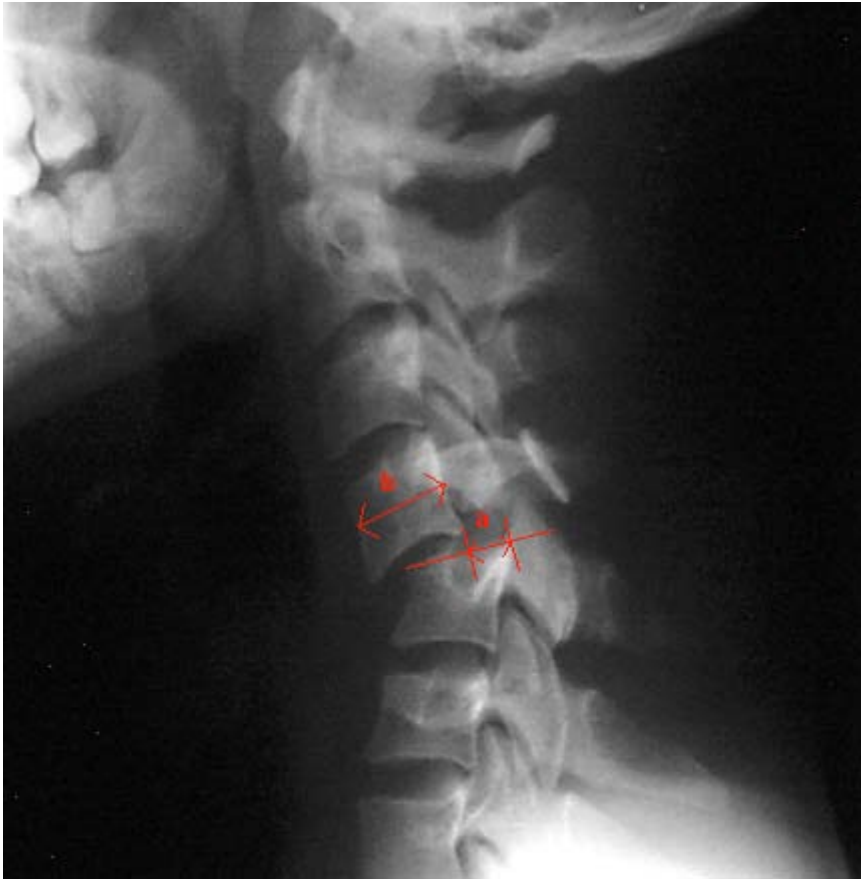Abnormal disc narrowing

Developmentally narrow spinal canal

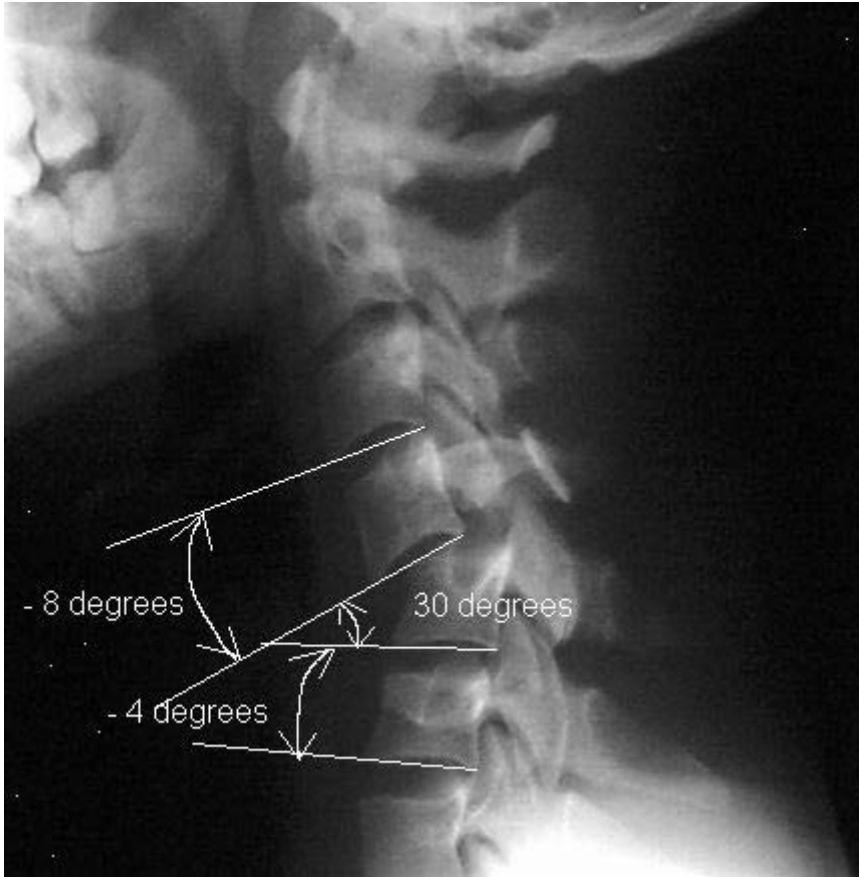
1. Sagittal diameter < 13 mm

OR

Media file 27: White and Panjabi Scoring Scale for Cervical Instability.



Media file 28: The distance (a) is measured from the posterior-inferior corner of the vertebral body above the allegedly unstable disk space, to the posterior-superior corner of the vertebral body below the allegedly unstable disk space. The distance (b) is the anterior-posterior sagittal-plane diameter of the vertebral body above the allegedly unstable disk space. According to White and Panjabi's outline, evidence of instability exists if the distance (a) is greater than 20% of distance (b). Alternatively, if the linear distance (a) is greater than 3.5 mm, instability is evident. In conclusion: If $(a)/(b) \times 100 > 20\%$, or if $(a) > 3.5$ mm, then instability is evident. In this example $(a) = 5.5$ mm, $(b) = 13.0$ mm. $5.5/13 \times 100 = 42.3\%$, and $42.3\% > 20\%$; therefore, instability is evident. Also, $(a) = 5.5$ mm, which is greater than 3.5 mm; therefore, instability is evident.



Media file 29: This is a schematic representation of White and Panjabi's description of abnormal angulation. The finding of abnormal angulation greater than 11° between supra-adjacent and subadjacent cervical motion segments on a static lateral cervical spine (C-spine) radiograph is considered unstable. The basic mathematical formula to analyze this is as follows: The angle of the motion segment in question minus the angle of the supra-adjacent segment or the subadjacent motion segment. The difference is less than 11° in the normally stable C-spine. In this image, the formula is illustrated by the following examples: For the supra-adjacent level: $30 - (-8) = 38$, $38 > 11$. For the subadjacent level $30 - (-4) = 34$, $34 > 11$.

References

1. Gill SS, Boden BP. The epidemiology of catastrophic spine injuries in high school and college football. *Sports Med Arthrosc.* Mar 2008;16(1):2-6. [\[Medline\]](#).
2. Boden BP, Jarvis CG. Spinal injuries in sports. *Neurol Clin.* Feb 2008;26(1):63-78; viii. [\[Medline\]](#).
3. Clarke KS. Epidemiology of athletic neck injury. *Clin Sports Med.* Jan 1998;17(1):83-97. [\[Medline\]](#).
4. Maroon JC, Bailes JE. Athletes with cervical spine injury. *Spine.* Oct 1 1996;21(19):2294-9. [\[Medline\]](#).
5. Olympia RP, Dixon T, Brady J, Avner JR. Emergency planning in school-based athletics: a national survey of athletic trainers. *Pediatr Emerg Care.* Oct 2007;23(10):703-8. [\[Medline\]](#).
6. Thomas BE, McCullen GM, Yuan HA. Cervical spine injuries in football players. *J Am Acad Orthop Surg.* Sep-Oct 1999;7(5):338-47. [\[Medline\]](#).
7. Fuller CW, Brooks JH, Kemp SP. Spinal injuries in professional rugby union: a prospective cohort study. *Clin J Sport Med.* Jan 2007;17(1):10-6. [\[Medline\]](#).

8. Lark SD, McCarthy PW. Cervical range of motion and proprioception in rugby players versus non-rugby players. *J Sports Sci.* Jun 2007;25(8):887-94. [\[Medline\]](#).
9. Langer PR, Fadale PD, Palumbo MA. Catastrophic neck injuries in the collision sport athlete. *Sports Med Arthrosc.* Mar 2008;16(1):7-15. [\[Medline\]](#).
10. Villavicencio AT, Hernández TD, Burneikiene S, Thramann J. Neck pain in multisport athletes. *J Neurosurg Spine.* Oct 2007;7(4):408-13. [\[Medline\]](#).
11. Bell K. On-field issues of the C-spine-injured helmeted athlete. *Curr Sports Med Rep.* Jan 2007;6(1):32-5. [\[Medline\]](#).
12. Meyer SA, Schulte KR, Callaghan JJ. Cervical spinal stenosis and stingers in collegiate football players. *Am J Sports Med.* Mar-Apr 1994;22(2):158-66. [\[Medline\]](#).
13. Weinstein SM. Assessment and rehabilitation of the athlete with a "stinger". A model for the management of noncatastrophic athletic cervical spine injury. *Clin Sports Med.* Jan 1998;17(1):127-35. [\[Medline\]](#).
14. Warren WL Jr, Bailes JE. On the field evaluation of athletic neck injury. *Clin Sports Med.* Jan 1998;17(1):99-110. [\[Medline\]](#).
15. Torg JS, Ramsey-Emrhein JA. Management guidelines for participation in collision activities with congenital, developmental, or post-injury lesions involving the cervical spine. *Clin Sports Med.* Jul 1997;16(3):501-30. [\[Medline\]](#).
16. Albright JP, Moses JM, Feldick HG, Dolan KD, Burmeister LF. Nonfatal cervical spine injuries in interscholastic football. *JAMA.* Sep 13 1976;236(11):1243-5. [\[Medline\]](#).
17. White AA 3rd, Johnson RM, Panjabi MM. Biomechanical analysis of clinical stability in the cervical spine. *Clin Orthop.* 1975;(109):85-96. [\[Medline\]](#).
18. White AA 3rd, Panjabi MM. Update on the evaluation of instability of the lower cervical spine. *Instr Course Lect.* 1987;36:513-20. [\[Medline\]](#).
19. Eismont FJ. Point of View regarding Magnetic Resonance Evaluation in Closed Traction Reduction of Cervical Dislocations by Vaccaro. *Spine.* 1999;24:1217.
20. Vaccaro AR, Falatyn SP, Flanders AE, et al. Magnetic resonance evaluation of the intervertebral disc, spinal ligaments, and spinal cord before and after closed traction reduction of cervical spine dislocations. *Spine.* Jun 15 1999;24(12):1210-7. [\[Medline\]](#).
21. Fehlings MG, Farhadi HF. Cervical stenosis, spinal cord neurapraxia, and the professional athlete. *J Neurosurg Spine.* Apr 2007;6(4):354-5; discussion 355. [\[Medline\]](#).
22. Torg JS, Pavlov H, Genuario SE. Neurapraxia of the cervical spinal cord with transient quadriplegia. *J Bone Joint Surg Am.* Dec 1986;68(9):1354-70. [\[Medline\]](#).
23. Herzog RJ, Wiens JJ, Dillingham MF. Normal cervical spine morphometry and cervical spinal stenosis in asymptomatic professional football players. Plain film radiography, multiplanar computed tomography, and magnetic resonance imaging. *Spine.* Jun 1991;16(6 Suppl):S178-86. [\[Medline\]](#).
24. Epstein JA, Carras R, Hyman RA. Cervical myelopathy caused by developmental stenosis of the spinal canal. *J Neurosurg.* Sep 1979;51(3):362-7. [\[Medline\]](#).
25. Eismont FJ, Clifford S, Goldberg M. Cervical sagittal spinal canal size in spine injury. *Spine.* Oct 1984;9(7):663-6. [\[Medline\]](#).

26. Cantu RC. The cervical spinal stenosis controversy. *Clin Sports Med*. Jan 1998;17(1):121-6. [\[Medline\]](#).
27. Watkins RG. Neck injuries in football players. *Clin Sports Med*. Apr 1986;5(2):215-46. [\[Medline\]](#).
28. Ellis JL, Gottlieb JE. Return-to-play decisions after cervical spine injuries. *Curr Sports Med Rep*. Jan 2007;6(1):56-61. [\[Medline\]](#).
29. Davis PM, McKelvey MK. Medicolegal aspects of athletic cervical spine injury. *Clin Sports Med*. Jan 1998;17(1):147-54. [\[Medline\]](#).

Keywords

C-spine injuries, back injury, brachial plexus injuries, cervical spine fracture, disk herniation, lower cervical spine fractures, sports-related spinal injury, sports-related back injury, neck injury, sports-related neck injury, sprain/strain

Contributor Information and Disclosures

Author

Andrew A Sama, MD, Director of Orthopedic Spine Surgery at the New York Hospital of Queens, Assistant Professor of Orthopedic Surgery at the Weill Medical College, Cornell University; Consulting Staff, Department of Orthopedic Surgery, Hospital for Special Surgery

Andrew A Sama, MD is a member of the following medical societies: Alpha Omega Alpha

Disclosure: Orthodevelopment Corporation Royalty for Implant Design & Development

Coauthor(s)

Federico P Girardi, MD, Instructor, Department of Orthopedic Surgery, Weill College of Medicine of Cornell University

Federico P Girardi, MD is a member of the following medical societies: Medical Society of the State of New York

Disclosure: Nothing to disclose

Frank P Cammisa, Jr, MD, Chief, Spinal Surgery Service, Director, Spine Care Institute, Hospital for Special Surgery; Associate Professor, Department of Clinical Orthopedic Surgery, Weill Medical College-Cornell University

Frank P Cammisa, Jr, MD is a member of the following medical societies: American Association for the Advancement of Science, American Medical Association, American Spinal Injury Association, Eastern

Orthopaedic Association, Medical Society of the State of New York, New York Academy of Sciences, New York County Medical Society, and North American Spine Society

Disclosure: Nothing to disclose

Medical Editor

James F Kellam, MD, Vice-Chair, Department of Orthopedic Surgery, Director of Orthopedic Trauma and Education, Carolinas Medical Center

James F Kellam, MD is a member of the following medical societies: American Academy of Orthopaedic Surgeons, Orthopaedic Trauma Association, and Royal College of Physicians and Surgeons of Canada

Disclosure: Nothing to disclose

Pharmacy Editor

Francisco Talavera, PharmD, PhD, Senior Pharmacy Editor, eMedicine

Disclosure: Nothing to disclose

Managing Editor

William O Shaffer, BS, MD, Professor, Vice-Chairman and Residency Program Director, Department of Orthopedic Surgery, University of Kentucky at Lexington

William O Shaffer, BS, MD is a member of the following medical societies: American Academy of Orthopaedic Surgeons, American Orthopaedic Association, International Society for the Study of the Lumbar Spine, Kentucky Medical Association, Kentucky Orthopaedic Society, North American Spine Society, Southern Medical Association, and Southern Orthopaedic Association

Disclosure: DePuySpine 1997-2007 (not presently) Royalty for Consulting; DePuySpine 2002-2007 (closed) Grant/research funds for SacroPelvic Instrumentation Biomechanical Study; DePuyBiologics 2005-2008 (closed) Grant/research funds for Healos study just closed

CME Editor

Dinesh Patel, MD, FACS, Associate Clinical Professor of Orthopedic Surgery, Harvard Medical School; Chief of Arthroscopic Surgery, Department of Orthopedic Surgery, Massachusetts General Hospital

Dinesh Patel, MD, FACS is a member of the following medical societies: American Academy of Orthopaedic Surgeons, American Association of Physicians of Indian Origin, American College of International Physicians, and American College of Surgeons

Disclosure: Nothing to disclose

Chief Editor

Mary Ann E Keenan, MD, Professor, Vice Chair for Graduate Medical Education, Department of Orthopedic Surgery, University of Pennsylvania School of Medicine; Chief of Neuro-Orthopedics Program, Department of Orthopedic Surgery, Hospital of the University of Pennsylvania

Mary Ann E Keenan, MD is a member of the following medical societies: Alpha Omega Alpha, American Academy of Orthopaedic Surgeons, American Orthopaedic Association, American Orthopaedic Foot and Ankle Society, American Society for Surgery of the Hand, and Orthopaedic Rehabilitation Association

Disclosure: Nothing to disclose

© 1994-2009 by Medscape.
All Rights Reserved
(<http://www.medscape.com/public/copyright>)